Svāsthya: Trends in General Medicine and Public Health
https://doi.org/10.70347/svsthya.v3i6.143

Short Communications

Effects of the combined administration of vitamin C and quercetin on urea and creatinine levels, histopathological features in ethanol-induced mice

Hermansyah Salwa Arastech[1*], Nabil Hajar[2], Lukman Faishal Fatharani[2], Bela Bagus Setiawan[2]

[1] Faculty of Medicine, Universitas Muhammadiyah Semarang, Semarang, Indonesia; [2] Department of Biomedical Sciences, Faculty of Medicine, Universitas Muhammadiyah Semarang, Gedung Fakultas Kedokteran UNIMUS, Jl. Kedungmundu Raya No. 18, Kel. Kedungmundu, Kec. Tembalang, Kota Semarang, Jawa Tengah 50273, Indonesia

ABSTRACT

Background: During ethanol metabolism, the generation of reactive oxygen species (ROS) can alter the structure and function of several organs, including the kidney. Serum urea and creatinine levels are routinely used to assess kidney function, and histopathological examination of renal tissue provides complementary information on structural injury. Vitamin C and quercetin possess antioxidant activity that may limit ethanol-induced renal injury. **Objective:** This study aimed to evaluate whether the combined administration of vitamin C and quercetin attenuates ethanol-induced changes in serum urea levels, serum creatinine levels, and renal histopathology in mice. **Methods**: A posttest-only control group design was applied to 30 male Swiss Webster mice randomly allocated to five groups of six animals: a negative control (K−); a positive control receiving 4 mL/kg body weight of ethanol (K+); and three groups receiving ethanol together with vitamin C and quercetin at 50 and 20 mg/kg (P1), 100 and 40 mg/kg (P2), and 200 and 80 mg/kg body weight (P3). After 28 days, serum urea and creatinine levels were measured, and the kidneys were processed for hematoxylin–eosin staining and semiquantitative scoring. Data were analyzed using the Kruskal–Wallis test followed by pairwise Mann–Whitney comparisons. **Results**: Serum urea levels did not differ significantly between groups (Kruskal–Wallis $p = 0.193$). Serum creatinine levels differed significantly ($p = 0.016$): they were higher in K+ than in K− ($p = 0.008$) and lower in P3 than in K+ ($p = 0.015$). Histopathological scores also differed significantly ($p < 0.01$), with lower scores in P2 and P3 than in K+ ($p < 0.05$). **Conclusion**: The combination of vitamin C and quercetin attenuated the ethanol-associated increase in serum creatinine levels and the severity of renal histopathological injury, with the clearest effect observed at vitamin C concentrations of 200 mg/kg and 80 mg/kg. Serum urea was unaffected. Because oxidative stress markers were not measured and the groups were small, these findings should be regarded as preliminary.

KEYWORDS
Antioxidant, ethanol, kidney injury, quercetin, renoprotection, vitamin C

ARTICLE INFO
Received Aug 19, 2025
Revised Nov 20, 2026
Accepted Nov 21, 2026
Online Nov 21, 2026

EDITOR
I Made Dwi Mertha Adnyana, M.Ked.Trop.

CORRESPONDENCE
Hermansyah Salwa Arastech, Faculty of Medicine, Universitas Muhammadiyah Semarang, email: hermansyahsalwa090@gmail.com

CITE THIS ARTICLE

Arastech, H. S., Hajar, N., Fatharani, L. F., & Setiawan, B. B. (2026). Effects of the combined administration of vitamin C and quercetin on urea and creatinine levels, histopathological features in ethanol-induced mice. *Svāsthya: Trends in General Medicine and Public Health*, 3(6), e143. https://doi.org/10.70347/svsthya.v3i6.143

Supplemental data for this article can be accessed online at https://doi.org/10.70347/svsthya.v3i6.143
©2026 The Author(s). Published with license by PT. Mega Science Indonesia
This is an Open Access article distributed under the terms of the Creative Commons Attribution-NonCommercial-NoDerivatives 4.0 International (CC BY-NC-ND 4.0). This license allows reusers to copy and distribute the material in any medium or format in unadapted form only, for noncommercial purposes only, and only so long as attribution is given to the creator. The terms on which this articlehas been published allow the posting of the Accepted Manuscript in a repository by the author(s) or with their consent.

INTRODUCTION

Acute and chronic alcohol consumption can impair kidney function. Structural and functional changes in the kidney, including disturbances in the regulation of body fluid volume and electrolyte composition, have been reported after alcohol intake [1]. In Indonesia, alcohol is legally regulated under Ministry of Trade Regulations (*Permendag*) No. 20/2014 and No. 06/2015. However, underage alcohol consumption remains insufficiently controlled, leading to an earlier onset of addiction and an increasing number of alcohol consumers in the general population [2].

The main component of alcoholic beverages is ethanol, which has toxic effects. Ethanol metabolism induces the formation of a microsomal ethanol-oxidizing system (MEOS), leading to free radical formation. These free radicals, also known as reactive oxygen species (ROS), are byproducts of alcohol metabolism and can cause tissue damage, inflammation, and cell death [3]. Free radicals damage organ tissue unless they are neutralized by endogenous antioxidant defenses [3,4]. Antioxidants are substances that limit cellular damage caused by free radicals. Vitamin C, or ascorbic acid, is a water-soluble micronutrient that acts as an electron donor and serves as a cofactor for a number of mammalian enzymes [5]. Antioxidants act by donating electrons to free radicals, thereby stabilizing them and reducing their harmful effects. These free radicals may originate from external sources or arise as byproducts of cellular metabolism [6,7].

In addition to vitamin C, other compounds with similar activity include flavonoids, such as quercetin. Quercetin is found in various vegetables and grains and has a wide range of pharmacological activities, including antioxidant, anti-inflammatory, and nephroprotective effects against nephrotoxic agents [8,9,10]. Each compound has been studied largely in isolation, and evidence on their combined administration during ethanol exposure remains limited. In combination, other nephrotoxic models have been used; for example, in chronic cyclosporine A nephrotoxicity, quercetin decreased blood urea nitrogen, serum creatinine, and renal malondialdehyde levels, and its combination with a lipid-soluble antioxidant abolished these changes such that neither compound was fully reversed alone [11]. Whether a comparable dose-dependent benefit occurs when vitamin C is combined with quercetin during chronic ethanol exposure and whether functional and structural indicators respond concordantly have not been established. On the basis of the aforementioned background, this study aimed to investigate the effects of combined vitamin C and quercetin administration on serum urea concentration, serum creatinine concentration, and renal histopathological features in mice induced with ethanol.

MATERIALS AND METHODS

Study design and animals

This study employed a posttest-only control group design, using 30 male Swiss Webster mice aged 3 months and weighing approximately 20 grams. The mice were randomly divided into five groups of six animals each: a negative control group (K–), a positive control group (K+) that received ethanol at a dose of 4 mL/kg body weight (BW), treatment group 1 (P1), which received ethanol at 4 mL/kg BW along with a combination of vitamin C (50 mg/kg BW) and quercetin (20 mg/kg BW), treatment group 2 (P2), which received ethanol and a combination of vitamin C (100 mg/kg BW) and quercetin (40 mg/kg BW), and treatment group 3 (P3), which received ethanol and a combination of vitamin C (200 mg/kg BW) and quercetin (80 mg/kg BW) [8,12–14]. All groups underwent a 7-day acclimatization period prior to the 28-day treatment phase. Reporting followed the ARRIVE 2.0 guidelines [15].

Sample collection and laboratory analysis

After 28 days of treatment, the mice were anesthetized using chloroform, and blood samples were collected via the orbital sinus using microhematocrit tubes and stored in microtubes. After blood collection, the kidneys were harvested by cervical dislocation. The blood samples were centrifuged at 3000 rpm for 10 minutes to obtain serum, which was subsequently used to measure the urea and creatinine concentrations.

Histopathological assessment

The kidneys were processed for histological slide preparation using hematoxylin–eosin staining. The histological slides were examined under 400× magnification, with five random fields of view selected from each sample. Microanatomical structures were evaluated using a scoring system based on the method described by Qodar (2018) [16]. The histopathological scoring categories are presented in Table 1.

Table 1. Renal histopathology scoring categories

Category	Damage criteria
1	No kidney tissue damage was observed, including tubular lumen dilation, accumulation of cellular debris within the lumen, tubular lumen vacuolization, Bowman's space widening, degeneration, hyperplasia, necrosis, or the presence of inclusion bodies
2	One to two criteria present
3	Three to five criteria present
4	Six to eight criteria present

Adapted from Qodar (2018) [16].

Statistical analysis

Histopathological scores were ordinal, and the serum variables were not assumed to be normally distributed; all outcomes were therefore analyzed using the Kruskal–Wallis test, followed by pairwise Mann–Whitney comparisons [17,18]. A p value less than 0.05 was considered to indicate statistical significance. No adjustment for multiple comparisons was applied. All the data were analyzed using R Studio 1.1.383.

RESULTS

Serum urea

The mean serum urea concentrations were 46.42 ± 19.43 mg/dL (K–), 57.74 ± 14.67 mg/dL (K+), 39.35 ± 9.29 mg/dL (P1), 54.77 ± 16.60 mg/dL (P2), and 41.77 ± 9.12 mg/dL (P3) (Table 2, Figure 1a). The results of the Kruskal–Wallis test revealed no statistically significant differences in serum urea concentrations among the groups (P = 0.193).

Table 2. Mean serum urea and creatinine concentrations in all groups

Group	Urea (mg/dL)	Creatinine (mg/dL)	Scored units (n)
K–	46.42 ± 19.43	0.094 ± 0.01*	9
K+	57.74 ± 14.67	0.134 ± 0.03	9
P1	39.35 ± 9.29	0.142 ± 0.04	9
P2	54.77 ± 16.60	0.110 ± 0.04	9
P3	41.77 ± 9.12	0.080 ± 0.04*	9

The data are presented as the mean ± standard deviation. Statistical analysis was performed using the Kruskal–Wallis test, followed by pairwise comparisons between groups using the Mann–Whitney U test. Urea: no statistically significant difference between the groups (Kruskal–Wallis p = 0.193). Creatinine levels were significantly different between groups (Kruskal–Wallis p = 0.016). *Significantly different from K+ (p < 0.05). Pairwise comparisons: K– vs. K+, p = 0.008; K+ vs. P3, p = 0.015; K– versus P1, p = 0.014; P1 vs. P3, p = 0.027. Scored units are histopathological observations entered into the ordinal analysis and are reported here for transparency; see the note in the Methods.

Serum creatinine

Kruskal–Wallis analysis of serum creatinine concentrations revealed a statistically significant difference among the experimental groups (p = 0.016), prompting further pairwise comparisons using the Mann–Whitney U test. Serum creatinine was significantly higher in K+ (0.134 ± 0.03 mg/dL) than in K– (0.094 ± 0.01 mg/dL) (p = 0.008), which is consistent with the ethanol-associated reduction in excretory function. Group P3 (200 mg/kg BW vitamin C and 80 mg/kg BW quercetin; 0.080 ± 0.04 mg/dL) differed significantly from K+ (p = 0.015) and had the lowest mean concentration of all the groups (Figure 1b). Significant differences were also observed

between K– and P1 (p = 0.014) and between P1 and P3 (p = 0.027), whereas P3 did not differ significantly from P2.

Renal histopathology

Histological examination of the kidney tissues revealed the most severe damage in the positive control group (K+), characterized by tubular lumen dilation, vacuolization, widening of Bowman's space, and accumulation of cellular debris (Figure 2). In group P1, similar structural damage was still observed. In group P2, no cellular debris was detected. Moreover, group P3 showed only mild structural changes, specifically tubular lumen dilation and Bowman's space widening. Histopathological kidney scores analyzed using the Kruskal–Wallis test revealed a statistically significant difference among the groups ($p < 0.01$), prompting post hoc analysis using the Mann–Whitney test.

The post hoc results revealed a significant difference between the negative control (K–) and positive control (K+) groups (p = 0.001), indicating that alcohol administration caused structural damage to the kidney, as evidenced by higher histopathology scores in category 3 (Figure 1c). Significant differences were also detected between groups K– and P1, P2, and P3 ($p < 0.05$). In the K– group, no histopathological damage was observed in any field of view across all the samples. In contrast, compared with the K–, P2, and P3 groups, the K+ group was significantly different ($p < 0.05$), reflecting reduced histopathological damage scores in several fields of view (Figure 1c). Compared with the K–, P2, and P3 groups, the P1 group also showed significant differences ($p < 0.05$).

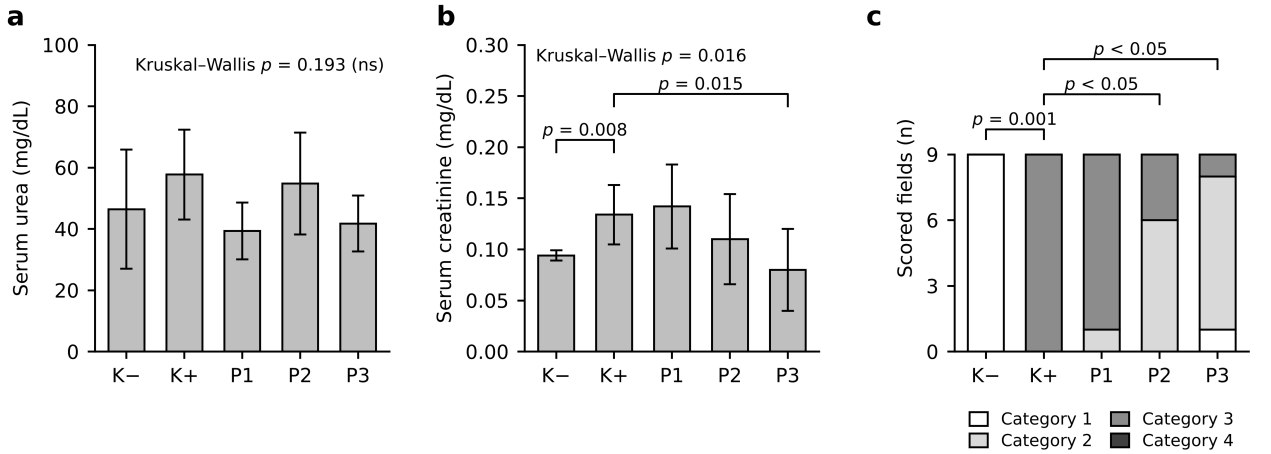

Figure 1. Distribution of serum urea (**a**), serum creatinine (**b**), and renal histopathology scores (**c**) across the groups. The bars in (a) and (b) show the mean and standard deviation, respectively; (c) shows the number of scored units in each damage category. K–, negative control; K+, positive control; P1–P3, treatment groups 1–3. Brackets indicate significant pairwise comparisons using the Mann–Whitney test.

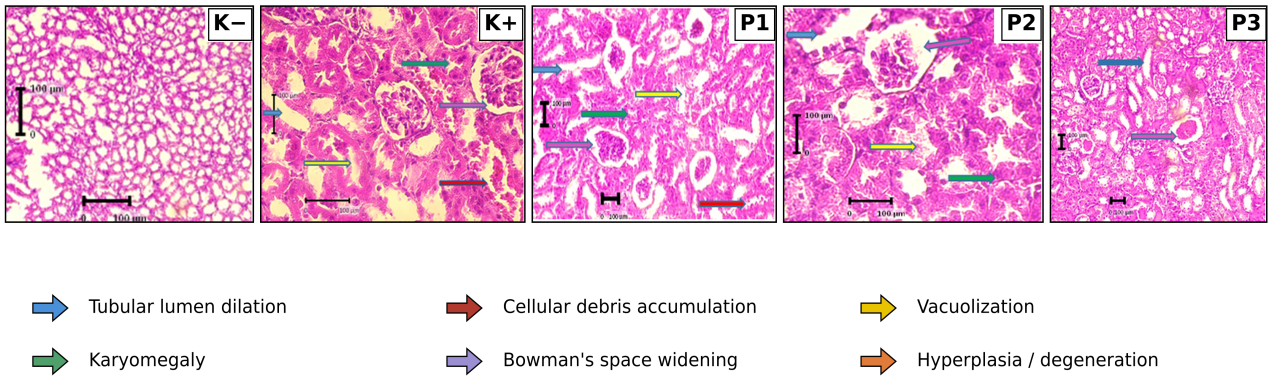

Figure 2. Representative renal histopathology in all groups (hematoxylin–eosin, 400×). K–, negative control; K+, positive control; P1–P3, treatment groups 1–3. Arrow colors denote the lesions listed in the legend. Scale bars are shown in each panel.

DISCUSSIONS

No statistically significant differences were observed in serum urea levels. This may be because ethanol administration did not substantially affect serum urea concentrations in mice during the exposure period studied. These findings are consistent with those of a previous study by Das et al. (2008) [19], which reported that alcohol administration for four weeks did not significantly affect renal biomarkers, whereas significant changes in serum urea were observed only after 12 weeks of treatment. Urea concentration is known to be influenced by several factors, including dietary protein intake, hydration status, and liver function, making it an unreliable sole indicator of renal impairment [20,21]. Because urea is synthesized in the liver, concurrent hepatic involvement during chronic ethanol exposure may counteract the increase driven by reduced glomerular filtration; thus, a stable urea concentration does not exclude renal injury [20,21].

In contrast to urea concentration, creatinine concentration is not influenced by dietary protein intake but depends on muscle mass and is therefore produced at a relatively constant rate. Ethanol is oxidized mainly by alcohol dehydrogenase to acetaldehyde, while chronic exposure induces the expression of cytochrome P450 2E1 (CYP2E1), a component of the microsomal ethanol-oxidizing system, in both the liver and kidney [22]. This alternative pathway increases oxidative stress and alters cell membrane phospholipids, which in turn activate immune cells such as neutrophil granulocytes. This immune response triggers inflammation in nephron cells and further increases oxidative stress in the kidneys, impairing their filtration function.

As a result, creatinine is not efficiently excreted into the urine, leading to elevated serum creatinine concentrations [25]. Chronic ethanol ingestion in rats increases renal lipid peroxidation, recruits myeloperoxidase-expressing leukocytes, induces apoptosis, and results in measurable increases in blood urea nitrogen and creatinine levels [23]. Experimental alcoholic nephropathy has the same effect, with increased renal expression of CYP2E1 and endoplasmic reticulum stress markers, increased expression of inflammatory mediators, and depletion of glutathione, superoxide dismutase, and catalase [24]. The elevated creatinine recorded in K+ is consistent with this pattern.

The lower creatinine levels and histopathological scores in P2 and P3 are consistent with the antioxidant and anti-inflammatory activities of these two compounds. Quercetin attenuated inflammatory signaling and lipid peroxidation [26], and in the cyclosporine A model, it restored renal antioxidant enzyme activity, whereas the combination of quercetin with a second antioxidant abolished the functional and biochemical changes in which neither compound was fully reversed alone [11]. A dose-dependent pattern of the same kind appeared in the present data: P1 did not differ from K+ in terms of either outcome, whereas P2 and P3 did, which suggests a threshold below which the combination confers no measurable protection. This interpretation remains indirect because no oxidative stress marker was measured here.

Based on the histopathological scoring results, a significant improvement in the renal histological structure of mice was observed. The group receiving ethanol alone showed consistent damage across all the fields of view, which was categorized as grade 3. These findings align with those of Yudhisthira et al. [27], who reported that alcohol metabolism produces acetaldehyde, leading to oxidative stress and elevated levels of reactive oxygen species (ROS). In the kidneys, this results in damage to both the glomeruli and renal tubules. Therefore, the administration of a combination of quercetin and vitamin C can be interpreted as providing protection against alcohol-induced renal histopathological damage through its antioxidant and anti-inflammatory activities [9,27].

Implications and future directions

Future studies should pair functional and structural endpoints with direct measurements of renal oxidative stress and inflammatory markers, include single-agent comparison groups to test whether the combination is additive or synergistic, extend observations beyond 28 days to capture the trajectory of injury and recovery, and verify systemic exposure to both compounds. Until such data are available, the present results are best interpreted as preliminary evidence of a dose-dependent renoprotective signal rather than as an established therapeutic effect.

Limitations

Several limitations qualify these findings. The groups were small, which limited the statistical power and precision of the estimates. Oxidative stress was inferred rather than measured, as malondialdehyde, superoxide dismutase, glutathione, and catalase were not assayed, leaving the proposed mechanism indirect. The design included no vitamin C alone and no quercetin alone, so the contribution of each compound and any true synergy cannot be separated. The histopathological assessment was semiquantitative and ordinal, and the blinding of the assessor was not reported. Pairwise comparisons were performed without correction for multiple testing, which increased the probability of a type I error across the set of comparisons reported. A single endpoint at 28 days was examined; therefore, neither the time course of injury nor its reversibility can be described. Finally, quercetin has low and variable oral bioavailability [26], and systemic exposure to either compound was not verified.

CONCLUSIONS

In ethanol-induced mice, the combined administration of vitamin C and quercetin was associated with lower serum creatinine levels and less severe renal histopathological changes, with the clearest effect observed with 200 mg/kg vitamin C and 80 mg/kg quercetin. Serum urea was unaffected. Given the small group sizes, absence of direct oxidative stress measurements, and lack of single-agent comparison groups, these results should be interpreted as preliminary evidence of a renoprotective effect that requires mechanistic confirmation.

CONFLICT OF INTEREST

The authors declare that the research was conducted in the absence of any commercial or financial relationships that could be construed as a potential conflict of interest.

AUTHOR CONTRIBUTIONS

Conceptualization, Methodology, Validation, Formal analysis, Investigation, Resources, Data curation, Writing – original draft, Writing – review and editing, Visualization, Supervision: HSA, NH, LFF, BBS.

FUNDING

This study did not receive any specific grant from funding agencies in the public, commercial, or not-for-profit sectors.

DECLARATION OF ARTIFICIAL INTELLIGENCE USE

We hereby confirm that no artificial intelligence (AI) tools or methodologies were utilized at any stage of this study, including during data collection, analysis, visualization, or manuscript preparation. All work presented in this study was conducted manually by the authors without the assistance of AI-based tools or systems.

REFERENCES

[1] Sandoval C, Vásquez B, Mandarim-de-Lacerda C, del Sol M. Ethanol intake and toxicity: in search of new treatments. Int J Morphol 2017;35:942–9. https://doi.org/10.4067/S0717-95022017000300024

[2] Kusumawardani N, Wiryawan Y, Anwar A, Handayani K, Angraeni S. Perilaku berisiko kesehatan pada pelajar SMP dan SMA di Indonesia. Jakarta: Badan Litbangkes Kementerian Kesehatan RI; 2016. https://cdn.who.int/media/docs/default-source/ncds/ncd-surveillance/data-reporting/indonesia/gshs/gshs-2015-indonesia-report-bahasa.pdf?sfvrsn=eb05c71c_2&download=true (accessed 28 April 2025).

[3] Varga ZV, Matyas C, Paloczi J, Pacher P. Alcohol misuse and kidney injury: epidemiological evidence and potential mechanisms. Alcohol Res 2017;38:283–8.
[4] Yanardag R, Ozsoy-Sacan O, Ozdil S, Bolkent S. Combined effects of vitamin C, vitamin E, and sodium selenate supplementation on absolute ethanol-induced injury in various organs of rats. Int J Toxicol 2007;26:513–23. https://doi.org/10.1080/10915810701707296
[5] Padayatty SJ, Levine M. Vitamin C: the known and the unknown and Goldilocks. Oral Dis 2016;22:463–93. https://doi.org/10.1111/odi.12446
[6] Arifin B, Ibrahim S. Struktur, bioaktivitas dan antioksidan flavonoid. J Zarah 2018;6. https://doi.org/10.31629/zarah.v6i1.313
[7] Purbayanti D. Efek konsumsi minuman beralkohol terhadap kadar kreatinin. J Surya Med 2018;4:44–50. https://doi.org/10.33084/jsm.v4i1.349
[8] Paunović MG, Ognjanović BI, Matić MM, Štajn AŠ, Saičić ZS. Protective effects of quercetin and vitamin C against nicotine-induced toxicity in the blood of Wistar rats. Arh Hig Rada Toksikol 2016;67:304–10. https://doi.org/10.1515/aiht-2016-67-2795
[9] Gomes IBS, Porto ML, Santos MCLFS, Campagnaro BP, Pereira TMC, Meyrelles SS, et al. Renoprotective, antioxidative and anti-apoptotic effects of oral low-dose quercetin in the C57BL/6J model of diabetic nephropathy. Lipids Health Dis 2014;13:184. https://doi.org/10.1186/1476-511X-13-184
[10] Shebeko SK, Zupanets IA, Propisnova VV. N-acetylglucosamine increases the efficacy of quercetin in the treatment of experimental acute kidney injury. J Pharm Pharmacogn Res 2020;8. https://doi.org/10.56499/jppres19.689_8.1.53
[11] Zal F, Mostafavi-Pour Z, Vessal M. Comparison of the effects of vitamin E and/or quercetin in attenuating chronic cyclosporine A-induced nephrotoxicity in male rats. Clin Exp Pharmacol Physiol 2007;34:720–4. https://doi.org/10.1111/j.1440-1681.2007.04623.x
[12] Bandiera S, Pulcinelli RR, Huf F, Almeida FB, Halmenschlager G, Bitencourt PER, et al. Hepatic and renal damage by alcohol and cigarette smoking in rats. Toxicol Res 2021;37:209–19. https://doi.org/10.1007/s43188-020-00057-y
[13] Hasanah U. Penentuan kadar vitamin C pada mangga kweni dengan menggunakan metode iodometri. J Kel Sehat Sejah 2018;16:90–5. https://doi.org/10.24114/jkss.v16i31.10176
[14] Primadevi S, Kresnadipayana D. Penetapan kadar etanol pada minuman beralkohol berbagai merk melalui pengukuran berat jenis. Biomedika 2016;9.
[15] Percie du Sert N, Hurst V, Ahluwalia A, Alam S, Avey MT, Baker M, et al. The ARRIVE guidelines 2.0: updated guidelines for reporting animal research. PLoS Biol 2020;18:e3000410. https://doi.org/10.1371/journal.pbio.3000410
[16] Qodar TS. Efek pemberian tepung kedelai (Glycine max (L.) Merr.) sebagai nefroprotektor terhadap gambaran histopatologi ginjal tikus Wistar jantan yang diinduksi diazinon [undergraduate thesis]. Jember: Universitas Jember; 2018.
[17] Trimawartinah T. Bahan ajar statistik non parametrik. 2020.
[18] Ostertagova E, Ostertag O, Kováč J. Methodology and application of the Kruskal–Wallis test. Appl Mech Mater 2014;611:115–20. https://doi.org/10.4028/www.scientific.net/AMM.611.115
[19] Das SK, Varadhan S, Dhanya L, Mukherjee S, Vasudevan DM. Effects of chronic ethanol exposure on renal function tests and oxidative stress in kidney. Indian J Clin Biochem 2008;23:341–4. https://doi.org/10.1007/s12291-008-0075-6
[20] Gounden V, Bhatt H, Jialal I. Renal function tests. In: StatPearls. Treasure Island (FL): StatPearls Publishing; 2023. https://www.ncbi.nlm.nih.gov/books/NBK507821/ (accessed 28 April 2025).
[21] Akinloye DI, Ugbaja RN, Dosumu OA, Rahman SA, Ugwor EI, James AS, et al. A time course study on dose–response relationship between alcohol exposure and its effects on lipid profile and biomarkers of tissue damage. Biochem Biophys Rep 2021;26:100927. https://doi.org/10.1016/j.bbrep.2021.100927
[22] Cederbaum AI. Alcohol metabolism. Clin Liver Dis 2012;16:667–85. https://doi.org/10.1016/j.cld.2012.08.002

[23] Latchoumycandane C, Nagy LE, McIntyre TM. Chronic ethanol ingestion induces oxidative kidney injury through taurine-inhibitable inflammation. Free Radic Biol Med 2014;69:403–16. https://doi.org/10.1016/j.freeradbiomed.2014.01.001

[24] Elnagar GM, Elseweidy MM, Elkomy NMIM, Al-Gabri NA, Shawky M. 10-Dehydrogingerdione ameliorates renal endoplasmic reticulum/oxidative stress and apoptosis in alcoholic nephropathy induced in experimental rats. Life Sci 2021;279:119673. https://doi.org/10.1016/j.lfs.2021.119673

[25] Latchoumycandane C, Nagy LE, McIntyre TM. Myeloperoxidase formation of PAF receptor ligands induces PAF receptor-dependent kidney injury during ethanol consumption. Free Radic Biol Med 2015;86:179–90. https://doi.org/10.1016/j.freeradbiomed.2015.05.020

[26] Li Y, Yao J, Han C, Yang J, Chaudhry MT, Wang S, et al. Quercetin, inflammation and immunity. Nutrients 2016;8:167. https://doi.org/10.3390/nu8030167

[27] Yudhisthira NL, Rahaju AS, Mustika A. Renal histopathology after mixed liquor consumption in Wistar rat. GSC Biol Pharm Sci 2022;20:324–9. https://doi.org/10.30574/gscbps.2022.20.3.0354